

From Tradition to Technology: Robotic Artificial Intelligence in Dental Implantology

Kaitlyn Huynh

Abstract

Dynamic navigation and haptic robotic systems are transforming the field of periodontology by enhancing the precision of implant placement. This is particularly vital in the maxillofacial region, where a comprehensive understanding of the nerves and vessels is essential to avoid critical structures. This article evaluates the impact of two major robotic systems, X-Guide and Yomi, on implant surgery outcomes, and compares them to the free-hand method. Recent studies reveal that implants placed via freehand techniques have a substantially higher inadequacy rate that is almost 3.5 times higher than robotic surgery placement. The X-Guide dynamic navigation system and Yomi robotics have both proven to enhance accuracy, both achieving mean deviations of no more than 1 mm from pre-planned positions. However, the high costs associated with these technologies may limit access for many practitioners. Despite these challenges, both systems facilitate the completion of complex cases with minimal deviations. In addition, their applications are expanding beyond implantology into areas like endodontics, further demonstrating their potential in modern dental practices.

1. Introduction

Dental implants are frequently utilized in oral rehabilitation because they offer highly successful, long-term solutions that maintain bone structure and reduce issues in surrounding teeth. They are typically made of titanium and are surgically embedded into the jawbone beneath the gum tissue to help address both partial and complete tooth loss [1].

1.1 Brief history of dental implants

The earliest documented use of dental implants dates back to 600 AD when the Mayan civilization innovatively employed shell materials to replace missing mandibular teeth [1]. Radiographs of Mayan mandibles reveal dense peri-implant bone formation similar to bone morphology around modern implants. In the 1940s, Formiggini, known as the Father of Modern Implantology, and Zepponi introduced an endosseous implant with a spiral stainless steel design [1]. Later, Dr. Perron Andres enhanced the design by adding a solid shaft. As implants continued developing in the 1940s, Swedish researcher Dahl pioneered subperiosteal (on the bone) implants. In 1967, Dr. Leonard Linkow introduced blade implants, including the Ventplant implant, enabling placement in both the maxilla and mandible [1, 2].

Brånemark, in 1952, discovered titanium could bond to bone when titanium chambers were placed in rabbit femurs for blood flow. He found they became firmly affixed and could not be removed. Brånemark coined osseointegration as “a direct structural and functional connection between ordered, living bone, and the surface of a load carrying implant” [1, 2]. Initially tested in 1965, Brånemark’s two-stage threaded titanium root-form implants, termed fixtures, were first applied in a patient with severe jaw deformities and dental anomalies. Four implants were

placed in the mandible, integrating within six months and maintaining functionality for 40 years [2].

1.2 Implant success

Today, dental implants have a ten-year success rate of 90% to 95%. Although widely favored by dentists, complications with dental implant placement and care continue to pose clinical challenges [3]. Periodontal diseases, often stemming from inadequate brushing and flossing, can contribute to the development of peri-implantitis by promoting plaque accumulation and hardening of biofilm. Peri-implantitis is an inflammatory condition induced by bacterial biofilm, affecting both the soft and hard tissues around dental implants. It resembles periodontitis but occurs around implants rather than natural teeth. Symptoms of peri-implantitis typically include bleeding on probing, suppuration, and progressive bone loss beyond normal physiological remodeling.

In severe cases, this condition can lead to implant failure and may require its removal [4]. In particular, multiple studies indicate that smoking elevates implant failure compared to nonsmokers, with reported failure rates ranging from 6.5% to 20%. While nicotine-induced vasoconstriction can cause bone loss, other studies show that implant failure stems from peri-implant tissue exposure to tobacco smoke rather than issues with healing or osseointegration [5].

Patient non-compliance is another challenge, as implants are vulnerable to plaque-related diseases. Adequate plaque control and regular dental follow-ups are essential to prevent peri-implantitis. Age-related factors, such as reduced manual dexterity and visual acuity, also affect implant outcomes [6].

1.3 Important anatomical features

Due to the distinct nature of dental implant surgery compared to other dental treatments, such as restorative and minimally invasive procedures, a comprehensive knowledge of the nerves and vessels in the maxillofacial region, including the maxilla and mandible, is crucial.

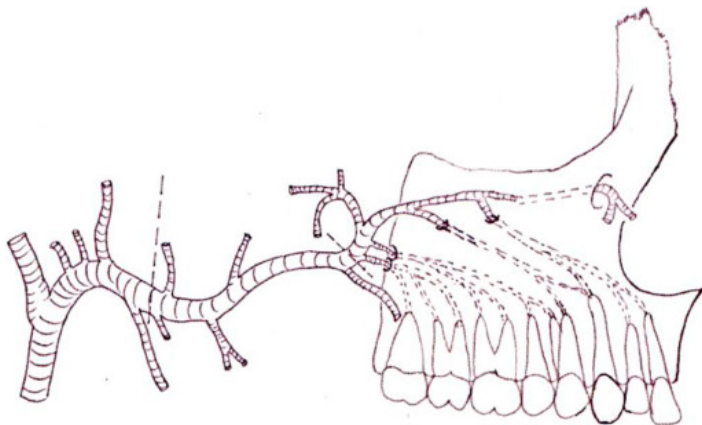


Figure 1. The posterior superior alveolar artery enters the alveolar foramen and runs through the alveolar canals.

Figure reproduced without modification from Reference 7 under the Creative Commons License (CC BY-NC-ND 4.0). The original article can be accessed at DOI: 10.1016/j.job.2021.01.002. For further details, please visit the Creative Commons License (<https://creativecommons.org/licenses/by-nc-nd/4.0/>).

The posterior superior alveolar artery, which originates from the maxillary artery, enters the alveolar foramen before it travels through the alveolar canals to supply the maxillary molars, gingiva, and buccal mucosa (Figure 1). These canals, visible in CT scans, require careful consideration during pterygoid implant placement or tissue harvesting to avoid damaging the artery. This artery also supplies the lateral wall of the maxillary sinus, and requires particular caution during sinus lift procedures—a technique used to provide sufficient bone in the maxillary (upper jaw) sinus to allow for the placement of dental implants [7].

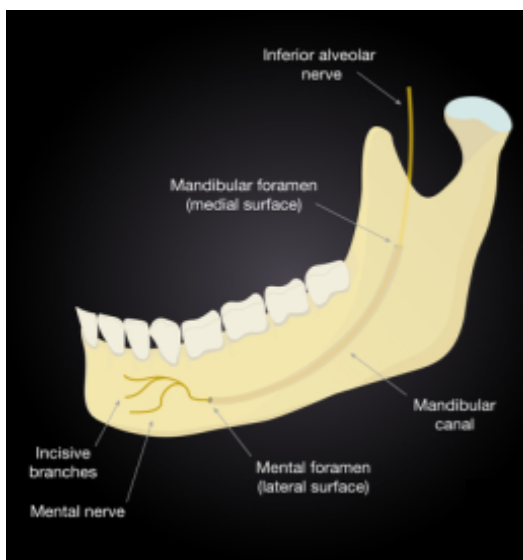

Figure 2. The figure shows the inferior alveolar nerve entering the mandible through the mandibular foramen and eventually exiting via the mental foramen.

Figure reproduced without modification from Reference 8 under the Creative Commons License (CC BY-NC 4.0). The original article can be accessed at DOI: 10.5125/jkaoms.2023.49.6.347. For further details, please visit the Creative Commons License (<https://creativecommons.org/licenses/by-nc/4.0/>).

The mandibular canal (MC), situated within the mandible, houses the inferior alveolar nerve (IAN) and artery. It begins at the mandibular foramen and extends to the mental foramen in the front. The IAN splits into the incisive and mental nerves. Maintaining the integrity of the IAN is critical as injuries to the nerve during implant procedures can lead to severe complications: for example, it can lead to altered sensation, paresthesia (tingling or numbness), or even complete nerve function loss in the chin, lower lip, and the skin overlying the anterior mandible [8].

The mental foramen is another crucial anatomical point, as the mental nerve is susceptible to damage during various dental procedures, including endodontics, extractions, and implant placement in the lower premolar and anterior mandible region. Such injuries can result in sensory disturbances in the lower third of the face [9].

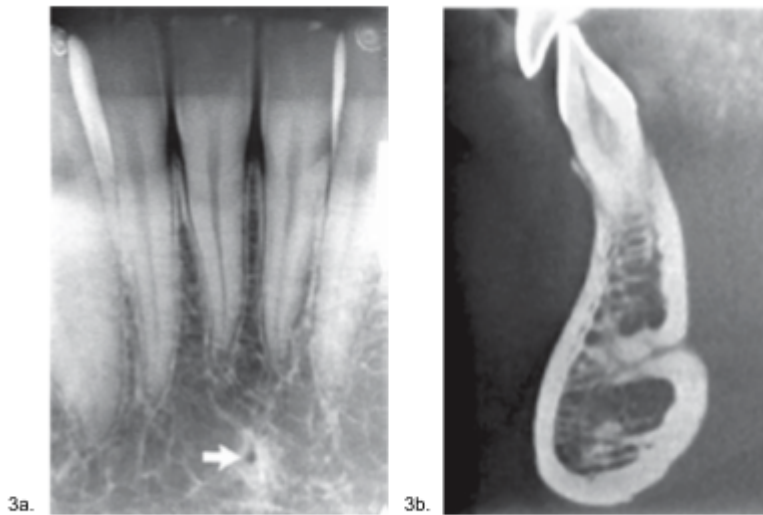


Figure 3. a: The lingual foramen, indicated by the arrow, is the small rounded opening shown in the intraoral periapical view. b: In the cross-sectional CBCT image, the lingual foramen extends deep into the mandible from the lingual surface.

Figure reproduced without modification from the original source, with adjusted labels (3a. and 3b.) for alignment with this paper, under the Creative Commons License (CC BY-NC-SA 4.0). The full article is available at DOI: 10.18231/j.jooo.2020.042. For further details, please visit the Creative Commons License (<https://creativecommons.org/licenses/by-nc-sa/4.0/>).

The lingual foramen (LF), a key structure in the anterior mandible, is typically found along the midline, either above or below the genial tubercle. Its location near the sublingual space is associated with a significant bleeding risk during surgery, making damage to the LF potentially life-threatening [10].

1.4 Implant planning

Obtaining an accurate imprint of the dental arch or area is critical to ensure surgical success and proper placement of a prosthesis. Implant planning begins with capturing precise 3D images of the jawbone obtained from Computed Tomography (CT) or Cone Beam Computed Tomography (CBCT) scans. CBCT is a radiographic imaging method that provides three-dimensional (3D) imaging of hard tissue structures, such as the jaw and teeth. CBCT has significantly lower radiation exposure than conventional CT scans (68 μSv versus 600 μSv). CBCT employs an X-ray beam that scans 360° around the patient, capturing single projection images, or “basis” images, at specific intervals. Advanced software programs are applied to the projection data to create a comprehensive 3D volumetric dataset in the axial, sagittal, and coronal planes [11].

After this step, an intra-oral scan of the patient is performed. Intraoral scanning (IOS) is based on 3D systems that capture detailed information on the shape and size of dental arches and the patient’s teeth and soft tissues. IOS is recognized as a superior alternative to conventional impressions as it reduces the risk of distortion associated with traditional impression materials, allows for quick error rescanning, and alleviates the discomfort and time-consuming nature of patients [12, 13]. The 3D data from the CBCT and intraoral scans are aligned to produce a

complete digital model of the patient's oral anatomy. Combining the bone structure details from CBCT with the dental arch specifics from the intraoral scan, this comprehensive model facilitates two primary guided surgery systems: static guidance and dynamic navigation [14].

"Static" refers to a system where the implant position is fixed according to the predetermined implant placement. It does not allow for real-time adjustments during the procedure. A static system employs Computer-Aided Design/Computer-Aided Manufacturing (CAD/CAM) stents with metal tubes and a surgical system. Specifically, the 3D data from the CBCT and intraoral scans are imported into CAD software for detailed planning. CAM technologies then use this information to create a precise surgical guide through rapid prototyping methods such as 3D printing and stereolithography [15]. These guides fit securely onto the existing dentition or edentulous area during surgery and help direct the surgeon to the predetermined sites to ensure the accuracy and protection of vital structures. However, drawbacks of this system include instrument misalignment due to restricted mouth opening, potential guide fractures, and the inability to make intraoperative adjustments during placement [14, 16].

On the other hand, dynamic navigation is a computer-guided navigation system that helps the clinician in real-time during the implant positioning through visual imaging tools on a monitor [14]. X-Guide, created by X-Nav Technologies, is a leading example of dynamic 3D navigation systems. These systems utilize optical tracking with passive or active arrays to track the position of the dental drill. Passive systems reflect light to cameras, while active systems emit light tracked by cameras. Some advantages to dynamic navigation over static systems include real-time adjustments, continuous visualization of the drill in three dimensions, and avoiding issues like guide displacement. However, some limitations include sensitivity to reflections, the need for a clear line of sight between the tracking device and cameras, more expensive, and a significant learning curve for uses [15].

1.5 Brief introduction to robotic-assisted implant surgery (RAIS)

Robot-assisted implant surgery enhances flexibility, stability, and accuracy in placing implants, addressing challenges like challenging working positions to obtain direct vision, operator fatigue, and human errors associated with traditional methods. Although robotic systems have a longer history in general medicine, they have also rapidly gained traction in dental surgery, leading to their integration across multiple dental disciplines, including prosthodontics, oral surgery, and implantology. As the demand for greater precision in dental implants grows, these robotic systems are being recognized for their advanced capabilities, such as robotic intelligence, machine vision, multi-sensor integration, and 3D visualization [17].

Dental robotic systems are categorized based on Haptic Robotic-Guided Systems. They combine haptic feedback, which refers to touch-based sensations that provide real-time information about interactions with the surgical site, with robotic guidance to ensure precise implant placement. These systems offer real-time visualization and tactile feedback, providing the static benefit of physical constraints and the dynamic advantages of same-day surgery and intraoperative adaptability [18].

Dental implant robotics have evolved to include various systems with differing levels of automation and user interaction. A typical dental implant robot comprises three primary

components: a robotic arm, a visual system, and a central control system. As outlined by Troccaz et al., these systems are categorized based on the level of user interaction during tool motion. Active robots autonomously carry out pre-planned motion, while passive robots operate manually, semi-active robots allow for constrained motion, and teleoperated robots hold the tool but are remotely controlled by the user [19]. Yomi is the first haptic robotic-guided system to receive FDA clearance, designed to drill using a coordinate system mapped onto teeth autonomously. Other dental implant robot systems have been introduced following Yomi's introduction including the Remebot and Dentbot [17].

This paper will systematically review and analyze advancements in robotic-assisted dental implant surgery, focusing on Yomi and X-Guide. By examining the applications, precision, and efficiency of these technologies, this review aims to offer insights into their potential to shape the future of implant dentistry.

2. Materials and Methods

This systematic review focused on the following question: In patients requiring implants, how has robotic artificial intelligence affected implant surgery outcomes and accuracy in the past and present?

The definitions of population, intervention, comparison, and outcome (PICO) were developed based on the focused question. They were defined as follows:

Population: patients requiring dental implants

Intervention: how has robotic artificial intelligence

Comparison: in the past and present

Outcomes: affected implant surgery

An electronic search was conducted without time or language restrictions using Pubmed, Google Scholar, ResearchGate, and other article databases. The reference lists of included studies and relevant reviews were also searched for other potential studies. The following keywords were used in our search: Robotic Dentistry, Dental Implants, Cone-Beam Computed Tomography, Navigated Surgery, Dynamic Navigation, Haptic Robot Guided Systems, Robotic-Assisted Implant Surgery, X-Guide, Yomi.

3. Discussion

3.1 Freehand method

Due to limited technology, dental implants have historically been placed freehand. This is called the freehand method because the surgeon relies solely on radiographs to evaluate the optimal location, depth, and angle for inserting implants without robotic assistance or static guides. Accuracy refers to the positional or angular deviation between the actual and planned implant

positions [20]. Thus, understanding the outcomes and complications associated with different methods is crucial.

Arisan et al. found that 54.65% of implants using the freehand method were classified as inadequately positioned, whereas this rate decreased to 15.78% with a mucosa-supported drilling template [21]. Other studies have similarly documented deviations between the virtual and actual implant positions using the freehand method: in a cadaver study, average deviations were 1.43 mm (range: 0.65–2.31 mm) at the implant shoulder, and 2.20 mm at the apex, with angular deviations ranging from 3.08° to 14.98° [22]. Likewise, Varga et al. observed average deviations of 1.82 mm (range: 0.56–5.38) at the implant shoulder and 2.43 mm (range: 0.54–4.83 mm) at the apex, with angular deviations ranging from 0.71° to 21.30° [23]. Aydemir and Arisan observed an average angular deviation of 10.04° (range: 2.19°–20.42°) using the freehand method, underscoring the consistent findings of significant angular deviations in clinical studies [24].

The precision attainable through freehand implant placement can vary significantly based on the surgeon's proficiency. In an *in vitro* study by Garcia et al., two researchers (one novice, one experienced) placed 36 implants in six resin mandible models using either the Navident dynamic navigation system or the freehand method. Experienced implant surgeons showed an average angular deviation of 6.69°, compared to 12.66° for less experienced surgeons, when comparing the actual implant position on postoperative CBCT to the virtual preoperative placement [21]. However, angled abutments can assist in correcting implant angulations when placing a prosthesis. Depending on the implant company, angles from 17-35 degrees can be corrected with angled custom abutments.

3.2 Pioneering surgical robotics

The development of dental implant robots has progressed significantly over the past two decades. In 2002, Boesecke et al. introduced the concept of an implant surgery robot at the University Hospital of Heidelberg: a prototype robot system from Medical Intelligence featuring a 700 mm reach and operated via PC-based TomoRob software. The system's function included maintaining the drill template alignment by preoperative plans [25]. In 2012, a 6-degree-of-freedom (DOF) autonomous robotic system utilized a volume-decomposition approach to insert a root-shaped dental implant [26]. In 2015, a 3-DOF implant surgery robot was developed, and a stereo vision-based navigation system was implemented. Designed to develop a cooperative guide system for precise starting point determination in dental implant surgery, it utilizes a modulated potential field approach to allow the surgeon to remote control the manipulator and avoid collisions [27]. In 2017, the Fourth Military Medical University Hospital in Xi'an and Beijing University collaborated to create an autonomous dental implant robot to tackle the significant shortage of skilled dentists in China. It has shown excellent outcomes, with data showing a mean entry deviation of 0.705 mm ± 0.145 mm, a mean apical deviation of 0.998 mm ± 0.232 mm, and a mean axial deviation of 2.077 mm ± 0.455 mm [26].

Although advancements are ongoing in the development of autonomous robots for dentistry, robotic systems have been much more prevalent in medicine. The origin of robot-assisted surgery can be traced back to work at NASA in the mid-1980s when they developed a remotely

controlled robotic system intended for surgical use in battlefield conditions and space missions [26]. In the year 2000, the FDA approved the first robotic system for laparoscopic surgery: Intuitive Surgical's *da Vinci Surgical System*. The da Vinci robot is a remote extension of the surgeon's hands, utilizing robotic arms with surgical instruments to perform precise procedures through small incisions. Since its introduction in 2000, the da Vinci robotic system has evolved through several generations, incorporating advancements such as better anatomical exposure, advanced imaging systems, and tremor-reduction features [28].

3.3 X-Guide by X-Nav Technologies

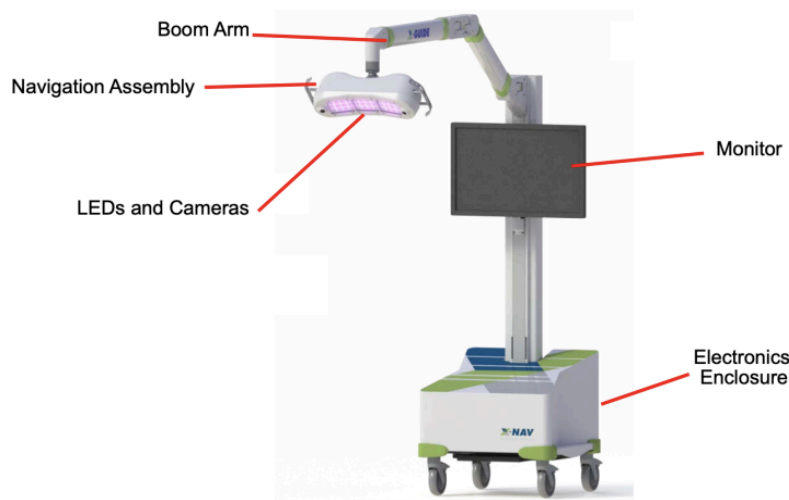


Figure 4. In the figure above, the X-Guide Surgical Navigation System's setup is shown. The mobile cart includes an LCD monitor, boom arm, navigation assembly, and electronics enclosure.

Figure reproduced without modification from the FDA 510(k) Summary - K232148. The FDA has waived all worldwide copyright rights under applicable law, allowing unrestricted use of the material.

Developed by X-Nav Technologies, X-Guide is a dynamic computer-assisted surgery system that relies on stereo triangulation from optical cameras, tracking the movement of two dynamic reference frames during surgery: one fixed to the patient's anatomy and the other to the surgeon's handpiece. The system processes this tracking data to deliver real-time guidance, a key benefit that enables surgeons to control drills with high precision [29].

Patient Tracker calibration determines the spatial relationship between the Patient Tracker and the patient's scan coordinates to ensure proper alignment. For partially edentulous patients, X-Clips with radiodense spheres are utilized, while edentulous patients use bone screws that serve as fiducials, effectively linking CT scans to their surgical anatomy. The X-Mark Registration process is suitable for both partially edentulous and edentulous patients. In this process, anatomical landmarks are marked directly on the CT scans by the surgeon, acting as fiducials. After identifying at least three landmarks, the surgeon uses a Probe Tool to link the Patient Tracker to the system, facilitating precise patient registration. The Digital Imaging and

Communications in Medicine (DICOM) data is then used for implant planning, with X-Guide's software offering features like parallel planning, virtual teeth, and nerve visualization. Calibration of the handpiece tracker and patient tracker to the 3D plan is done before surgery to provide live guidance during osteotomy. Postoperative CBCT scans are used to verify the accuracy of implant placement by comparing planned and final positions [30].

The X-Guide offers several advantages over traditional static guides. It facilitates same-day scanning, surgical planning, and surgery without requiring laboratory-fabricated stents, making the procedure more time- and cost-efficient. Additionally, the system allows surgeons to maintain an unobstructed view of the surgical site, as there is no stent blocking the field. Plans can be altered more easily during surgery, and the entire field can be visualized at all times. For challenging cases, such as those involving limited mouth opening, narrow interdental spaces, distal implant placements, or patients with a pronounced gag reflex, the X-Guide can be highly beneficial [29].

In a study by Emery et al. 2016, the X-Guide system demonstrated high accuracy on dental models. Eleven dentate maxilla and ten dentate mandible polyurethane models, each receiving a single implant to ensure independent measurements, were used to simulate surgical anatomy. The deviations from the planned implant location to the final implant location for the dentate models were $0.89^\circ \pm 0.35^\circ$ in angular deviation and 0.38 ± 0.21 mm in global apex position [29]. Furthermore, both studies by Block et al. (2017) and Nickenig et al. (2009) found that the X-Guide system outperforms freehand methods in implant placement accuracy. Block et al.'s prospective study, involving 478 patients and 714 implants, reported a mean angular deviation of $2.97 \pm 2.09^\circ$, a mean global platform position deviation of 1.16 ± 0.59 mm, and a mean global apical position deviation of 1.29 ± 0.65 mm [31]. In Nickenig et al.'s study, the X-Guide achieved an average shoulder deviation of 0.9 mm and an apex deviation of 0.6-0.9 mm, while the freehand method had deviations of 2.4-3.5 mm at the shoulder and 2.0-2.5 mm at the apex [32].

In the study by Wang et al. in 2022, using the X-Guide system, a total of 72 implants were placed by three experienced practitioners and three novice practitioners. The mean entry deviation of both experienced and novice practitioners was ~ 1.12 mm, the mean apex 3D deviation was ~ 1.66 mm, and the mean apex vertical deviation was ~ 0.57 mm. The angular deviation ranged from 1.25° to 6.68° . These minimal deviations highlight the X-Guide system's superior precision. Although Wang et al.'s study focuses on how experience affects dental implant placement, the results showed no significant differences between experienced and novice practitioners [33].

Navigation-guided surgeries face several challenges, including human errors like minor hand tremors and perceptual inaccuracies, which can impact procedural precision. Device-related issues, like failures of infrared cameras, data cables, or monitor carts, can pose significant obstacles. A complete breakdown of the navigation system will force the procedure being completed freehand. This underscores the importance of thorough preoperative checks to ensure system reliability [34].

3.4 Yomi dental robot

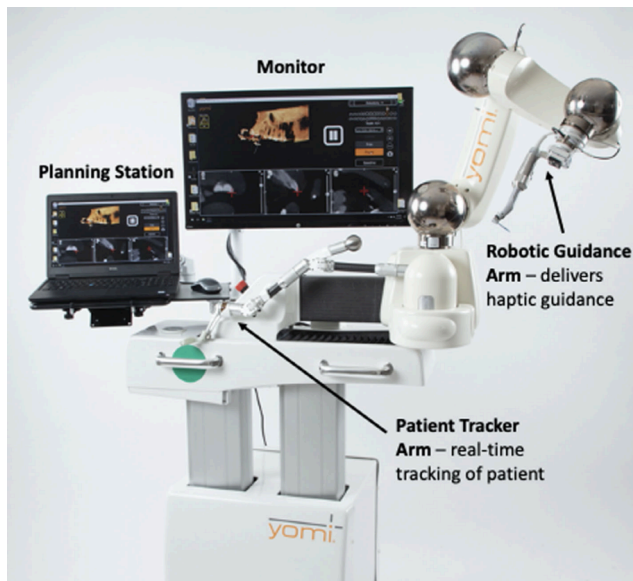


Figure 5. The figure above displays the Yomi system, outlining its design and key features.

Figure reproduced without modification from Reference 37 under the Creative Commons License (CC BY 4.0). The full article can be accessed at DOI: 10.1111/cid.13279. For further details, please visit the Creative Commons License (<https://creativecommons.org/licenses/by/4.0/>).

Yomi is the first FDA-cleared haptic robotic-guided system for dental procedures in March 2017. The robotic system integrates haptic feedback with robotic guidance, providing tactile sensations to the surgeon to maintain precise control over surgical instruments. During surgery, Yomi offers real-time feedback on location, angulation, and depth, ensuring alignment with pre-planned implant positions. This system combines the physical constraints of a surgical guide with the real-time feedback of dynamic navigation systems [18, 35].

The Yomi system comprises several essential components: the planning laptop and monitor are utilized for pre-operative planning and continuous monitoring throughout the procedure. The tracker arm is meant for real-time anatomical mapping of the patient to a virtual model, enabling dynamic adjustments to patient movements and ensuring precise instrument alignment without requiring patient immobilization or continuous line-of-sight infrared tracking. For the Robotic Guidance arm, the surgeon maneuvers the robotic handpiece, which is attached to the robotic guidance arm, with high precision towards the pre-planned implant position accurately [18, 35].

Using bite registration, the Yomi workflow begins by securing a surgical splint to the opposite side of the dental arch where the implant will be placed. Once a fiducial marker is attached, a CBCT scan is conducted to align the splint with the patient's dental anatomy. Implant planning is completed using Yomi's software, which allows for precise mapping of implant location and critical structures. The software also aids in planning the final prosthetic restoration. During the procedure, Yomi's robotic arm, attached to the splint, tracks the patient's position. Once a pre-selected landmark is confirmed on the CBCT scan, the robot's guidance arm and drill are

locked into place based on the digital plan. Live visualization on the monitor ensures precise execution, while intraoral checks confirm the accuracy of each step in the procedure [36].

Yomi offers several advantages in dental implantology. It provides real-time feedback during implant placement, ensuring precise control, and does not require a specific drill or implant. Additionally, surgery can be done on the same day, and Yomi has the capability for continuous use without rest, which reduces the risk of human error due to fatigue [18]. The system's design improves ergonomics for the surgeon, with fewer obstructions such as surgical guides and drill keys. Also, the system not only offers clear tactile feedback but also helpful audio and visual cues throughout the procedure, enhancing overall clarity through its multi-sensory approach.

Yomi's stability as a robotic system has demonstrated its ability to reduce inaccuracies in implant placement. In a clinical study conducted by Dr. Neugarten in 2023 involving 108 patients and 273 implants, the Yomi robot demonstrated high accuracy relative to the pre-operative plan with a mean angular deviation of 1.42° and minimal deviations of 1mm. Specifically, the mean coronal and apical deviations were 1.10 mm and 1.12 mm, respectively, significantly lower than the freehand and static guided method. The discussion noted no significant differences in deviations between the mandible and maxilla [18]. Similarly, in a publication by Dr. Ali in 2023, Yomi was used to place six implants in the maxilla and five in the lower mandible in a 61-year-old female. All the implants were placed with a high degree of accuracy compared to the pre-operative plan, as reported by the mean angular deviation of 2.58° , the mean global coronal of 0.98 mm, and the mean global apical of 1.06 mm [37]. Furthermore, in a study by Bolding et al. published in 2021, twenty-three implants were placed in the mandible and 15 in the maxilla between 5 participants. The mean angular deviation was 2.56° , with a global coronal deviation of 1.04 ± 0.70 mm from the plan and a global apical deviation of 0.95 ± 0.73 mm. The signed depth deviation was 0.42 ± 0.46 mm proud [38].

Despite these benefits, Yomi does have some drawbacks. An experienced dentist must continuously monitor the robot, as it does not replace a surgeon's judgment, experience, or decision-making skills. Patient acceptance can vary significantly due to unease about robotic-assisted surgeries. The price of Yomi in the United States is approximately \$200,000, making it inaccessible for many dental professionals [15]. Although additional long-term clinical studies are needed to evaluate outcomes and compare them with non-robotic methods, haptic robotic preparation offers significant intraoperative benefits for treating completely edentulous arches [38].

3.5 Differences between Yomi and X-Guide

When considering advanced dental implant systems, understanding the distinctions between Yomi and X-Guide is crucial for dentists to determine which technology aligns best with their practice needs and patient outcomes. The technology types are distinct. With Yomi, the robotic arm physically restricts the drill and offers resistance to incorrect movements, while also providing visualization on the monitor. In contrast, the X-Guide only displays real-time guidance on a monitor, leaving it up to the surgeon to manually maintain the correct trajectory. In terms of cost, both systems are notably expensive, with the X-Guide incurring high expenses primarily due to its advanced hardware components. However, the Yomi system is even more costly,

often rendering it inaccessible for many dental practitioners. Additionally, both Yomi and X-Guide present a considerable learning curve for implant surgeons.

When comparing the accuracy of both systems, it is clear that both Yomi and X-Guide provide significant improvements in precision over freehand techniques and static guides. Notably, the two largest sample size studies were Dr. Neugarten's study with Yomi, which showed a mean angular deviation of 1.42° across 273 implants, and Block et al.'s study with the X-Guide, which reported a mean angular deviation of $2.97 \pm 2.09^\circ$ for 714 implants [18, 31]. The slightly higher deviation observed with the X-Guide may be influenced by its sample size, which was nearly 40% larger. Despite this, both systems maintained deviations around 1mm, showcasing their high precision. These findings suggest that both Yomi and X-Guide are effective, reliable, and capable of delivering accurate results across a wide range of cases, making them suitable for clinical applications requiring precise implant placement. As technology continues to advance, enhancements in software and reductions in costs could make robotic systems, such as Yomi, more affordable, which may lead to their broader adoption in dental implantology.

3.6 Complex cases

Dental implant surgeries involving simultaneous sinus augmentation are also challenging due to the anatomical complexities surrounding the maxillary sinus and the limited native bone available. These complex cases require precision to avoid perforating the sinus membrane. Therefore, using Yomi robotics allows for enhanced accuracy, particularly in areas close to vital structures, such as the maxillary sinus [36].

One such case, detailed by Dr. Mergelmyer in 2022 and shown in Figure 6, involved a 67-year-old male patient with less than 5mm of native bone in the furcation of the tooth and concurrent left maxillary sinusitis. The tooth had been deemed unrestorable after an endodontic evaluation and was removed. Due to the limited bone height, an open (Caldwell-Luc) left maxillary sinus augmentation was performed to prepare for implant placement. A full-thickness flap was elevated under IV sedation and using Yomi robotic guidance, and a lateral window approach was created. The Schneiderian membrane was carefully elevated to accommodate the graft material. The dental implant osteotomy was completed using the Straumann protocol [36].

In another case by Dr. Mergelmeyer (2022), shown in Figure 7, a 56-year-old male presented with a missing tooth #14, which was previously extracted due to a vertical fracture. Despite only 7 mm of bone height and a large mucus retention cyst in the left maxillary sinus, implant placement was planned using Yomi robotic guidance. A closed sinus lift (Summers' Technique) was performed with simultaneous placement of a 4.8 x 10 mm implant. The sinus floor was elevated by 3mm, and graft materials were applied. Post-op imaging showed successful bone augmentation [38].

Similarly, full-arch rehabilitation in patients with atrophic, edentulous jaws poses significant challenges due to the limited bone quality and quantity, making implant placement more complex. A 2020 study by Lopes et al. presented a case of a 57-year-old female who required maxillary full-arch rehabilitation to address both aesthetic and functional concerns. The All-on-4 treatment was utilized, and it involved placing two anterior axial implants and two posterior tilted

implants. Dynamic navigation via the X-Guide system provided real-time guidance for precise implant placement, helping avoid key anatomical structures like the maxillary sinus and nasal cavities. After tooth extraction and bone regularization, four NobelParallel CC implants were placed with insertion torques above 35 N/cm, allowing for the immediate connection of a provisional prosthesis. This approach achieved both immediate functionality and aesthetic improvement on the same day, showcasing the success of the dynamic navigation-assisted workflow [39].

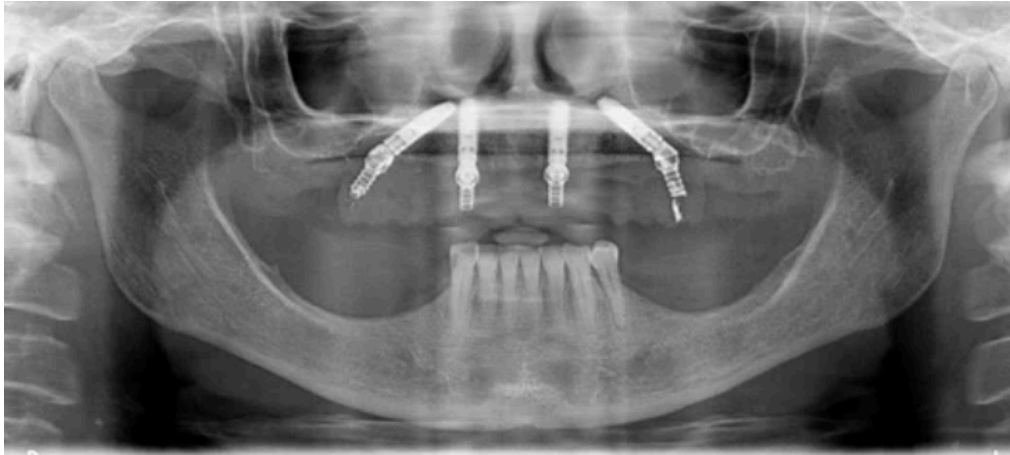


Figure 6. The figure shows a post-operative orthopantomography of maxillary rehabilitation performed using the All-on-4 concept with X-Guide's live navigation system.

Figure reproduced without modification from Reference 39 under the Creative Commons License (CC BY 4.0). The full article can be accessed at DOI: 10.3390/jcm9020421. For further details, please visit the Creative Commons License (<http://creativecommons.org/licenses/by/4.0/>).

In another challenging case report in Lopes et al.'s study, a 70-year-old hypertensive female required the completion of her maxillary full-arch rehabilitation after the failure of a previously placed tilted implant. Due to the insufficient residual bone in the posterior maxilla, classified as D-V under the Cawood and Howell system, a zygomatic implant was chosen. She was using the All-on-4 Hybrid rehabilitation concept, which combined three standard implants with one zygomatic implant. The X-Guide dynamic navigation system was employed to ensure precise placement, avoiding critical structures like the infra-orbital nerve and base of the orbit. A NobelZygoma 45 mm implant was successfully inserted with an insertion torque over 50 N/cm. This approach provided a reliable and functional solution for full-arch rehabilitation, although opportunities for improvement in the fiducial markers protocol were noted to streamline the surgical process [39].

Endodontic procedures, like root-end resection, are highly complex due to their precision-dependent nature. This surgery's intricate nature demands removing all ramifications and lateral canals. Success rates fluctuate from 17% to 96%, mainly because the techniques require meticulous execution to ensure optimal outcomes [40]. A study by Martinho et al. explored whether three-dimensional dynamic navigation systems, specifically using X-Guide software by X-Nav Technologies, could enhance accuracy and efficiency in osteotomy and root-end resection. The study involved both novice and experienced endodontists and revealed



that the X-Guide could significantly reduce accuracy deviations while halving procedure times. While novices couldn't match the precision of experienced endodontists, the X-Guide System notably improved their performance, highlighting its efficacy in complex endodontic cases [41].

Conclusion

Robotic implant surgery has increased the accuracy of implant placement and thus possibly lowering failure rates or the prevalence of peri-implant disease. Implants placed using a mucosa-supported drilling template demonstrated 3.5 times fewer inadequately positioned implants compared to the freehand method. Additionally, studies have shown dental implant robots in China have shown excellent outcomes with low mean entry deviations, and this can also be seen in X-Guide and Yomi achieving small deviations from the pre-planned positions.

The extensive studies and cases explored in this paper illustrate how dynamic navigation and haptic technologies, particularly X-Guide and Yomi, significantly minimize human error and improve outcomes, reinforcing their significance in contemporary dentistry. However, there remains considerable potential for further application. The studies reviewed indicate that systems like Yomi and X-Guide are already making strides in improving accuracy in various dental fields, such as endodontics. Extending the application of these systems into specialized fields is vital for enhancing patient outcomes and driving progress in clinical care.

References

1. Gupta R, Gupta N, Weber, DDS KK. Dental Implants. [Updated 2023 Aug 8]. In: StatPearls [Internet]. Treasure Island (FL): StatPearls Publishing; 2024 Jan-. Available from: <https://www.ncbi.nlm.nih.gov/books/NBK470448/>
2. Abraham, Celeste M. "A brief historical perspective on dental implants, their surface coatings and treatments." *The open dentistry journal* vol. 8 50-5. 16 May. 2014, doi:10.2174/1874210601408010050
3. Raikar, Sonal et al. "Factors Affecting the Survival Rate of Dental Implants: A Retrospective Study." *Journal of International Society of Preventive & Community Dentistry* vol. 7,6 (2017): 351-355. doi:10.4103/jispcd.JISPCD_380_17
4. Assery, Nasser M et al. "Peri-implantitis and systemic inflammation: A critical update." *The Saudi dental journal* vol. 35,5 (2023): 443-450. doi:10.1016/j.sdentj.2023.04.005
5. Kasat, V, and R Ladda. "Smoking and dental implants." *Journal of International Society of Preventive & Community Dentistry* vol. 2,2 (2012): 38-41. doi:10.4103/2231-0762.109358
6. Cortellini, Simone et al. "Patient compliance as a risk factor for the outcome of implant treatment." *Periodontology 2000* vol. 81,1 (2019): 209-225. doi:10.1111/prd.12293
7. Kageyama, Ikuo et al. "Importance of anatomy in dental implant surgery." *Journal of oral biosciences* vol. 63,2 (2021): 142-152. doi:10.1016/j.job.2021.01.002
8. Kim, Doogyum et al. "Implant placement with inferior alveolar nerve repositioning in the posterior mandible." *Journal of the Korean Association of Oral and Maxillofacial Surgeons* vol. 49,6 (2023): 347-353. doi:10.5125/jkaoms.2023.49.6.347
9. Cellina, Michaela, et al. "Anatomy of the mental foramen: Relationship among different metrical parameters for accurate localization." *Applied Sciences*, vol. 13, no. 16, 14 Aug. 2023, p. 9235, <https://doi.org/10.3390/app13169235>.
10. Padhye, Ninad Milind et al. "Three-dimensional assessment of the mandibular lingual foramina with implications for surgical and implant therapy: A multicentre cross-sectional study." *Journal of oral biology and craniofacial research* vol. 13,2 (2023): 186-190. doi:10.1016/j.jobcr.2023.01.002
11. Kumar, Mohan et al. "Cone beam computed tomography - know its secrets." *Journal of international oral health : JIOH* vol. 7,2 (2015): 64-8.
12. Angelone, Francesca et al. "Diagnostic Applications of Intraoral Scanners: A Systematic Review." *Journal of imaging* vol. 9,7 134. 3 Jul. 2023, doi:10.3390/jimaging9070134
13. Siqueira, Rafael et al. "Intraoral scanning reduces procedure time and improves patient comfort in fixed prosthodontics and implant dentistry: a systematic review." *Clinical oral investigations* vol. 25,12 (2021): 6517-6531. doi:10.1007/s00784-021-04157-3
14. Ramasamy, Manikandan et al. "Implant surgical guides: From the past to the present." *Journal of pharmacy & bioallied sciences* vol. 5,Suppl 1 (2013): S98-S102. doi:10.4103/0975-7406.113306
15. Yeshwante, Babita, et al. "Mastering Dental Implant Placement: A Review." *Journal of Applied Dental and Medical Sciences*, vol. 3, no. 2, spring 2017, pp. 220–227.
16. Gargallo-Albiol, Jordi et al. "Advantages and disadvantages of implant navigation surgery. A systematic review." *Annals of anatomy = Anatomischer Anzeiger : official organ of the Anatomische Gesellschaft* vol. 225 (2019): 1-10. doi:10.1016/j.aanat.2019.04.005

17. Wang, MiaoZhen et al. "Robot-assisted surgery for dental implant placement: A narrative review." *Journal of dentistry* vol. 146 (2024): 105034. doi:10.1016/j.jdent.2024.105034
18. Neugarten, Jay M. "Accuracy and Precision of Haptic Robotic-Guided Implant Surgery in a Large Consecutive Series." *The International journal of oral & maxillofacial implants* vol. 39,1 (2024): 99-106. doi:10.11607/jomi.10468
19. Troccaz, Jocelyne et al. "Frontiers of Medical Robotics: From Concept to Systems to Clinical Translation." *Annual review of biomedical engineering* vol. 21 (2019): 193-218. doi:10.1146/annurev-bioeng-060418-052502
20. Huang, Lixuan et al. "Evaluation of the accuracy of implant placement by using implant positional guide versus freehand: a prospective clinical study." *International journal of implant dentistry* vol. 9,1 45. 1 Dec. 2023, doi:10.1186/s40729-023-00512-z
21. Schnutenhaus, Sigmar et al. "Factors Influencing the Accuracy of Freehand Implant Placement: A Prospective Clinical Study." *Dentistry journal* vol. 9,5 54. 10 May. 2021, doi:10.3390/dj9050054
22. Chen, Zhaozhao et al. "Accuracy of flapless immediate implant placement in anterior maxilla using computer-assisted versus freehand surgery: A cadaver study." *Clinical oral implants research* vol. 29,12 (2018): 1186-1194. doi:10.1111/clr.13382
23. Varga, Endre Jr et al. "Guidance means accuracy: A randomized clinical trial on freehand versus guided dental implantation." *Clinical oral implants research* vol. 31,5 (2020): 417-430. doi:10.1111/clr.13578
24. Aydemir, Ceyda Aktolun, and Volkan Arisan. "Accuracy of dental implant placement via dynamic navigation or the freehand method: A split-mouth randomized controlled clinical trial." *Clinical oral implants research* vol. 31,3 (2020): 255-263. doi:10.1111/clr.13563
25. Boesecke, R., et al. "Robot assistant for Dental Implantology." *Lecture Notes in Computer Science*, 5 Oct. 2001, pp. 1302–1303, https://doi.org/10.1007/3-540-45468-3_204.
26. Ahmad, Paras et al. "Dental Robotics: A Disruptive Technology." *Sensors (Basel, Switzerland)* vol. 21,10 3308. 11 May. 2021, doi:10.3390/s21103308
27. K. Yu, S. Uozumi, K. Ohnishi, S. Usuda, H. Kawana and T. Nakagawa, "Stereo vision based robot navigation system using modulated potential field for implant surgery," 2015 IEEE International Conference on Industrial Technology (ICIT), Seville, Spain, 2015, pp. 493-498, doi: 10.1109/ICIT.2015.7125147.
28. Rivero-Moreno, Yeisson et al. "Robotic Surgery: A Comprehensive Review of the Literature and Current Trends." *Cureus* vol. 15,7 e42370. 24 Jul. 2023, doi:10.7759/cureus.42370
29. Emery, Robert W et al. "Accuracy of Dynamic Navigation for Dental Implant Placement-Model-Based Evaluation." *The Journal of oral implantology* vol. 42,5 (2016): 399-405. doi:10.1563/aaid-joi-D-16-00025
30. 510(k) Summary - K232148. (2024). Accessed: October 24, 2024: https://www.accessdata.fda.gov/cdrh_docs/pdf23/K232148.pdf.
31. Block, Michael S et al. "Implant Placement Is More Accurate Using Dynamic Navigation." *Journal of oral and maxillofacial surgery : official journal of the American Association of Oral and Maxillofacial Surgeons* vol. 75,7 (2017): 1377-1386. doi:10.1016/j.joms.2017.02.026
32. Nickenig, Hans-Joachim et al. "Evaluation of the difference in accuracy between implant placement by virtual planning data and surgical guide templates versus the conventional free-hand method - a combined in vivo - in vitro technique using cone-beam CT (Part II)."

- Journal of cranio-maxillo-facial surgery : official publication of the European Association for Cranio-Maxillo-Facial Surgery* vol. 38,7 (2010): 488-93.
doi:10.1016/j.jcms.2009.10.023
33. Wang, Xiaotong et al. "Influence of experience on dental implant placement: an in vitro comparison of freehand, static guided and dynamic navigation approaches." *International journal of implant dentistry* vol. 8,1 42. 10 Oct. 2022, doi:10.1186/s40729-022-00441-3
34. Wu, Yiqun et al. "Reliability and accuracy of dynamic navigation for zygomatic implant placement." *Clinical oral implants research* vol. 33,4 (2022): 362-376.
doi:10.1111/clr.13897
35. Wiedemann, Thomas G. "Robotically Assisted Implant Surgery in Clinical Practice and Dental Education." *Today's FDA*, vol. 35, 2023, pp. 45–47.
36. Ali, Mohamed. "Flapless dental implant surgery enabled by haptic robotic guidance: A case report." *Clinical implant dentistry and related research* vol. 26,2 (2024): 251-257.
doi:10.1111/cid.13279
37. Bolding, Scotty L, and Uday N Reebye. "Accuracy of haptic robotic guidance of dental implant surgery for completely edentulous arches." *The Journal of prosthetic dentistry* vol. 128,4 (2022): 639-647. doi:10.1016/j.prosdent.2020.12.048
38. Mergelmeyer, James. "Dental Implant Surgeries with Simultaneous Sinus Augmentation Utilizing Yomi Robotics." *Impressions*, vol. 46, no. 3, summer 2022, pp. 29–32.
39. Lopes, Armando et al. "The Workflow of a New Dynamic Navigation System for the Insertion of Dental Implants in the Rehabilitation of Edentulous Jaws: Report of Two Cases." *Journal of clinical medicine* vol. 9,2 421. 4 Feb. 2020, doi:10.3390/jcm9020421
40. Antal, M., Nagy, E., Braunitzer, G. et al. Accuracy and clinical safety of guided root end resection with a trephine: a case series. *Head Face Med* 15, 30 (2019).
<https://doi.org/10.1186/s13005-019-0214-8>
41. Martinho, Frederico C et al. "Comparison of the Accuracy and Efficiency of a 3-Dimensional Dynamic Navigation System for Osteotomy and Root-end Resection Performed by Novice and Experienced Endodontists." *Journal of endodontics* vol. 48,10 (2022): 1327-1333.e1. doi:10.1016/j.joen.2022.07.001